



Evaluation of Suspected Pancreatic Cancer

October 15, 2015


If you experience technical difficulty during the presentation:

Contact WebEx Technical Support directly at:
US Toll Free: 1-866-779-3239
Toll Only: 1-408-435 -7088

or

Submit a question to the Event Producer via the Q&A Panel


For international support numbers visit:
<http://support.webex.com/support/phone-numbers.ht>



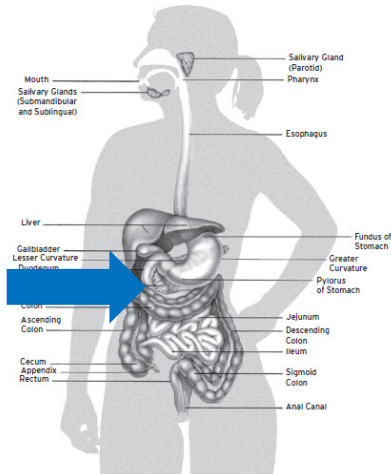
Evaluation of Suspected Pancreatic Cancer




Timothy B. Gardner, MD MS
Associate Professor of Medicine
Dartmouth Medical School
Section of Gastroenterology and Hepatology
Dartmouth-Hitchcock Medical Center



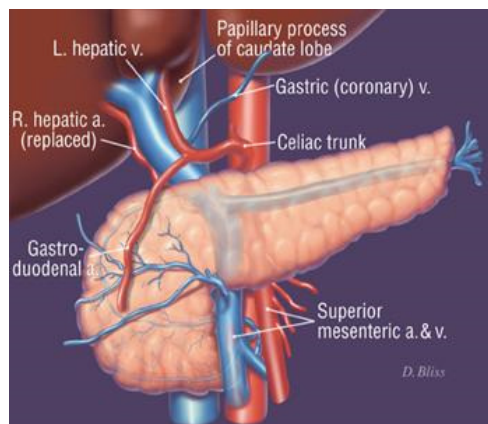
The Digestive System



© DARTMOUTH-HITCHCOCK. ALL RIGHTS RESERVED.

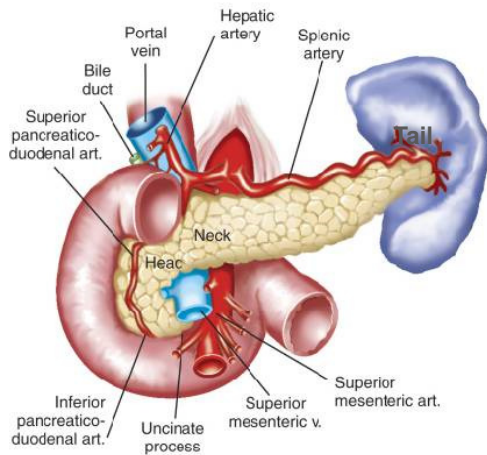


Normal Pancreatic Anatomy



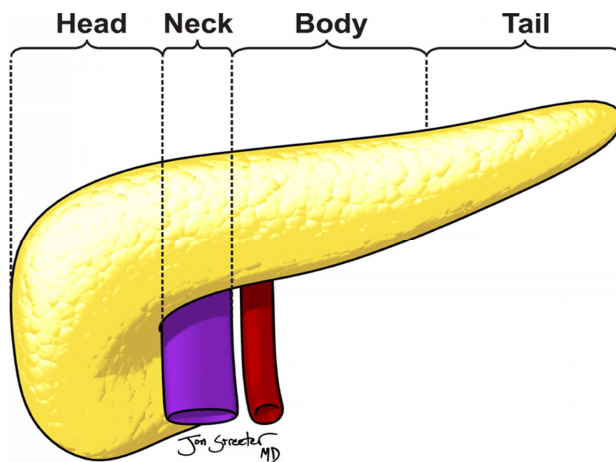
© DARTMOUTH-HITCHCOCK. ALL RIGHTS RESERVED.

Normal Pancreatic Anatomy




© DARTMOUTH-HITCHCOCK. ALL RIGHTS RESERVED.

Normal Pancreatic Anatomy



Mortelé K J et al. Radiographics 2006;26:715-731

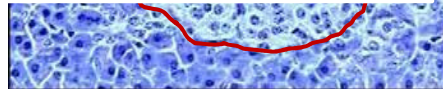
© DARTMOUTH-HITCHCOCK. ALL RIGHTS RESERVED.




Two Major Pancreas Functions

We are focusing on Diseases of the ***DIGESTION*** function of the pancreas today!

fatty foods and proteins in the intestine



© DARTMOUTH-HITCHCOCK. ALL RIGHTS RESERVED.



What is Cancer?

- An abnormal growth of tissue
- Can occur anywhere in any tissue
- Characterized by abnormal RATE and PATTERN of growth
- Immune to body's own checks and balances

© DARTMOUTH-HITCHCOCK. ALL RIGHTS RESERVED.



Causes of Cancer

ACQUIRED:

- Infectious
- Industrial/Environmental (radiation, chemicals)
- Vices (tobacco, alcohol, diet)

INHERITED:

- Familial predisposition
- Inherited cancer syndromes

© DARTMOUTH-HITCHCOCK. ALL RIGHTS RESERVED.



Pancreatic Cancer

ADENOCARCINOMA

- Most common
- Grows out of duct cells

NEUROENDOCRINE

- Much less common
- Derived from endocrine cells
- Slower growing, better prognosis

© DARTMOUTH-HITCHCOCK. ALL RIGHTS RESERVED.



Adenocarcinoma

- “Pancreatic Cancer”
- ~50,000 patients in USA per year
- 10th in incidence/4th in death rates

© DARTMOUTH-HITCHCOCK. ALL RIGHTS RESERVED.



Risk Factors

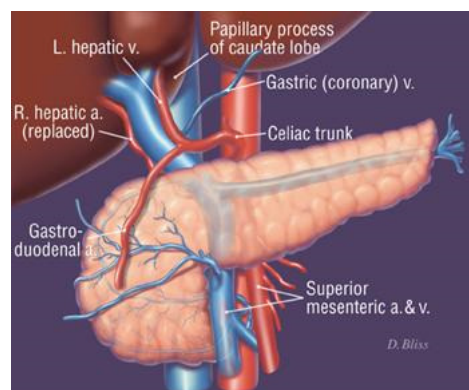
- Cigarette Smoking
- Age > 50 years
- Pancreatitis
- 5 - 10% of pancreas cancer inherited
- No “pancreas cancer gene” yet identified

© DARTMOUTH-HITCHCOCK. ALL RIGHTS RESERVED.

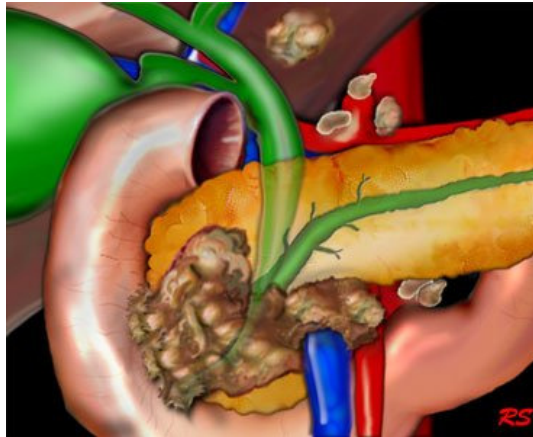
Pancreatic Adenocarcinoma

- Early spread through blood stream and lymph nodes
- Most patients have metastatic disease when diagnosed
- Disease confined to pancreas in <20% of patients

Normal Anatomy



Pancreatic Cancer



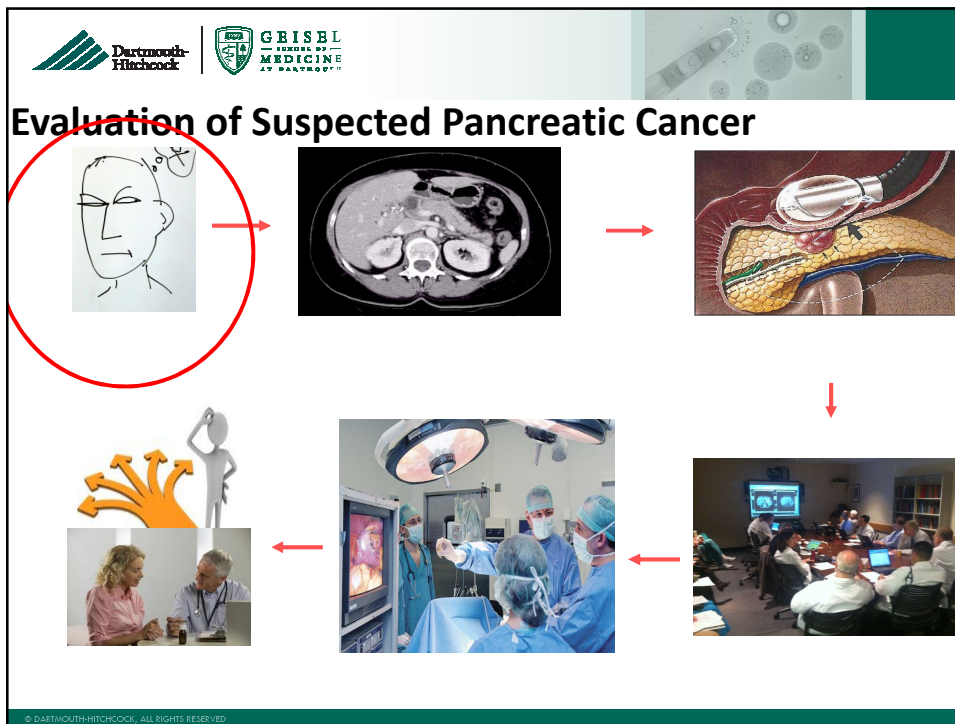
© DARTMOUTH-HITCHCOCK. ALL RIGHTS RESERVED.

Pancreatic Adenocarcinoma



- Most occur in head (75%)
- Minority body (15%), tail (10%)

© DARTMOUTH-HITCHCOCK. ALL RIGHTS RESERVED.





Clinical Suspicion

- PAIN
- JAUNDICE
LIGHT COLORED STOOL
DARKENED URINE
- LOSS OF APPETITE, WEIGHT LOSS
- BLOOD CLOTS, BLEEDING

The slide includes two images: a close-up of a human eye with a yellowish tint (jaundice) and a side-by-side comparison of a man's face, showing significant weight loss between the two images.



© DARTMOUTH-HITCHECOCK. ALL RIGHTS RESERVED.

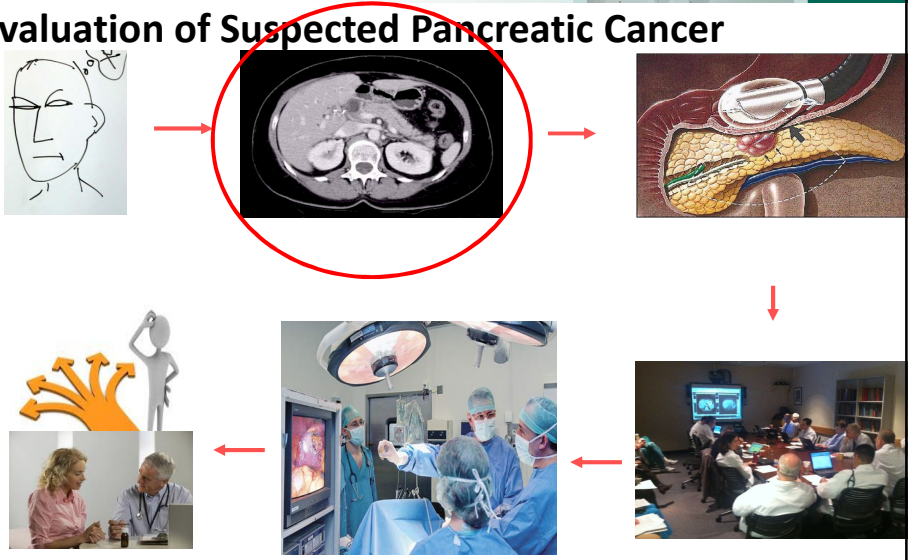
Diabetes and Pancreatic Cancer

- Up to 60% of patients develop diabetes in the months prior to diagnosis
- Those with diabetes often develop difficult to control blood sugar
- We believe there is a chemical made by the tumor that causes the pancreas not to make insulin effectively

© DARTMOUTH-HITCHCOCK. ALL RIGHTS RESERVED.

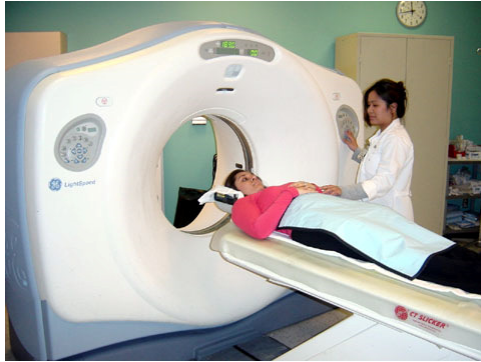Evaluation of Suspected Pancreatic Cancer



The flowchart illustrates the clinical pathway for suspected pancreatic cancer. It begins with a patient's face, leading to a CT scan of the abdomen (highlighted with a red circle). This leads to a diagram of the pancreas and its associated vessels. From there, the process moves to a multidisciplinary team meeting, then to a surgical procedure in an operating room, and finally to a consultation with a patient and a family member.

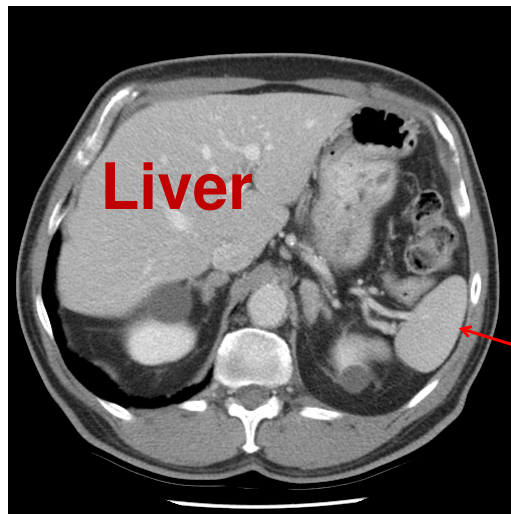
© DARTMOUTH-HITCHCOCK. ALL RIGHTS RESERVED.

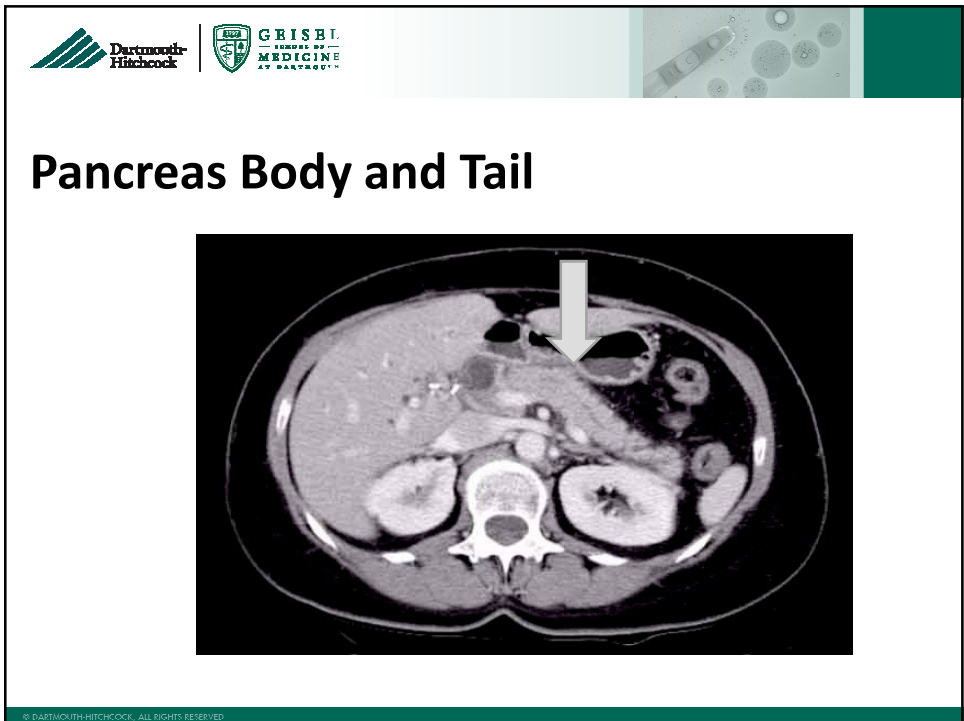
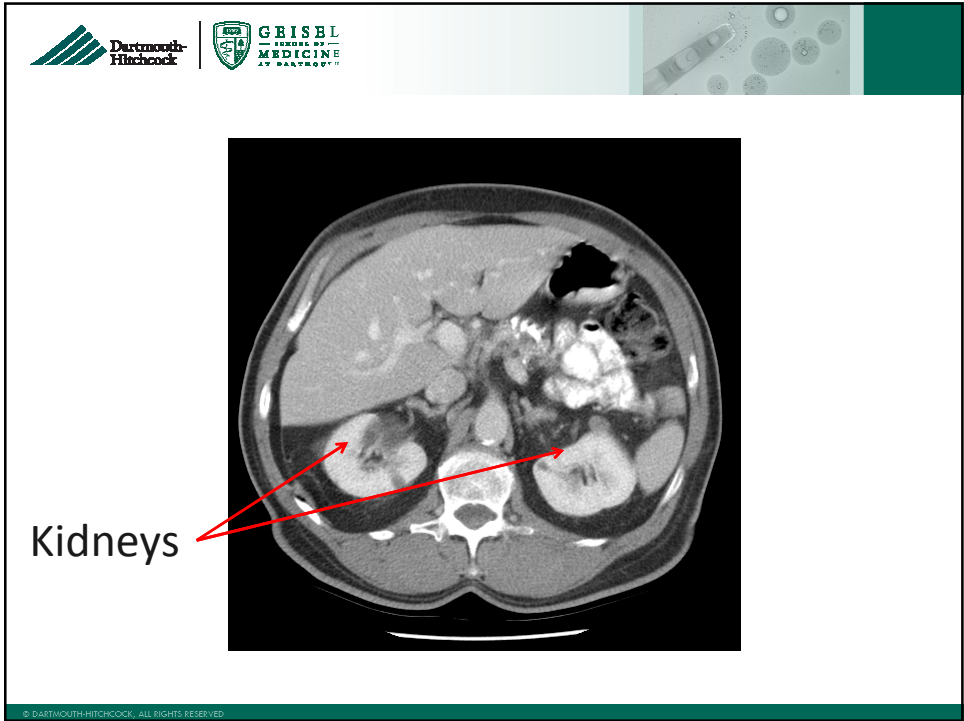
CT Pancreas



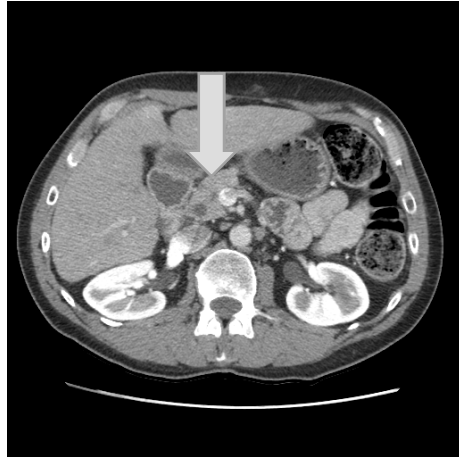- CT most utilized modality for pancreatic imaging
- Excellent sensitivity and local staging info
- Can help to distinguish masses
- Important to optimize technique

CT Scan



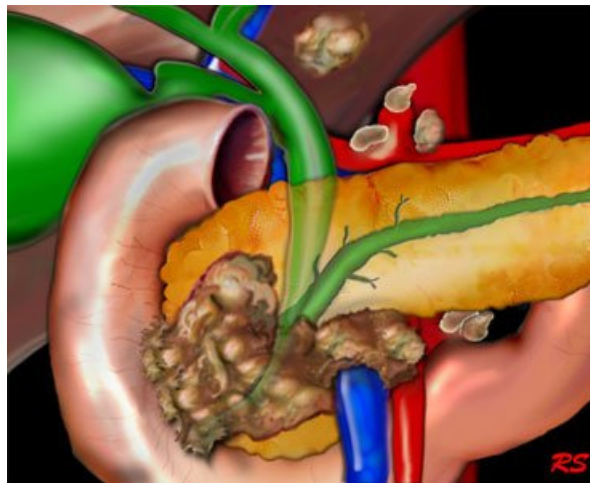


Pancreas Head



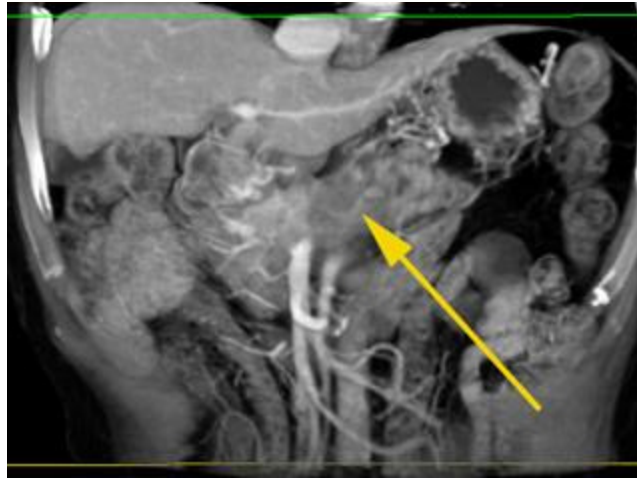© DARTMOUTH-HITCHCOCK. ALL RIGHTS RESERVED.

Pancreatic Neoplasm



© DARTMOUTH-HITCHCOCK. ALL RIGHTS RESERVED.

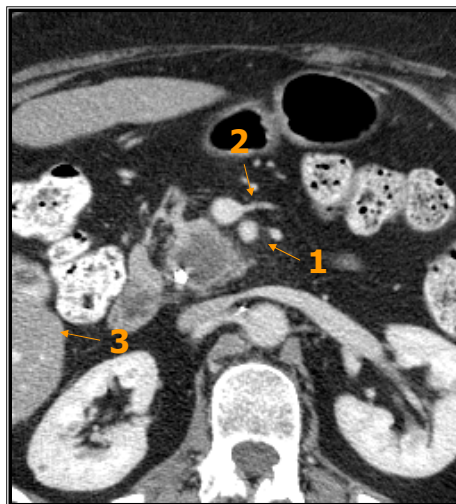
Pancreatic Cancer: Can it be removed?




© DARTMOUTH-HITCHCOCK. ALL RIGHTS RESERVED.

Technically Resectable PC

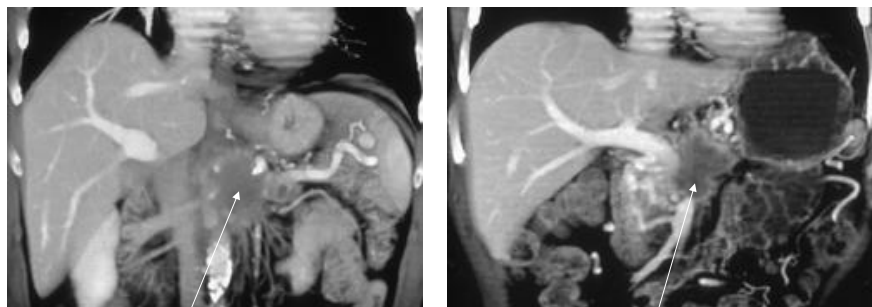
1. Tissue plane between tumor and SMA
2. Patent SMV-PV confluence
3. Absence of extrapancreatic disease



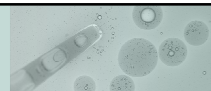
© DARTMOUTH-HITCHCOCK. ALL RIGHTS RESERVED.



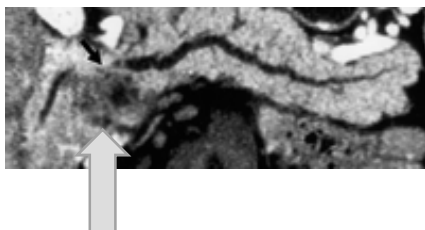
Pancreatic Cancer: CT



© DARTMOUTH-HITCHCOCK. ALL RIGHTS RESERVED.



Pancreatic Cancer: Patient Example



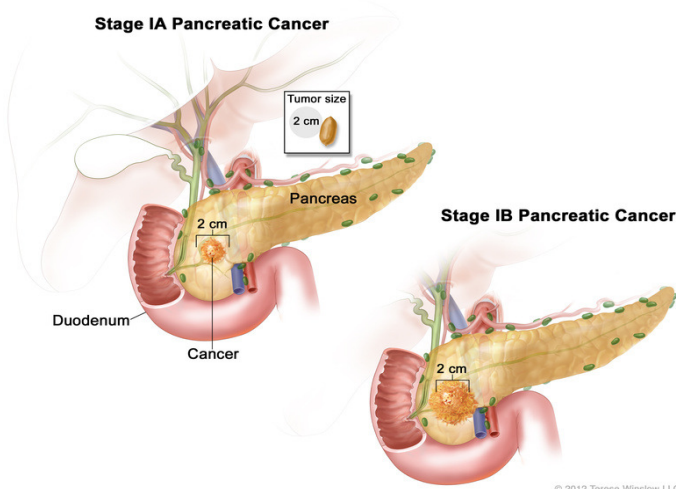
- 56 y/o female with adenocarcinoma
- Resectable
- Low attenuating mass
- Relative dilatation of middle and distal pancreatic duct

Prokesch, et al. Radiology, 225 (2002)

© DARTMOUTH-HITCHCOCK. ALL RIGHTS RESERVED.

Cancer Staging

Stage IA Pancreatic Cancer

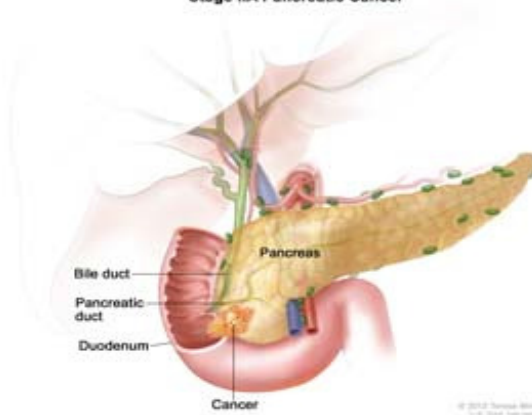


© 2012 Terese Winslow LLC
U.S. Govt. has certain rights

© DARTMOUTH-HITCHCOCK. ALL RIGHTS RESERVED.

Cancer Staging

Stage IIA Pancreatic Cancer

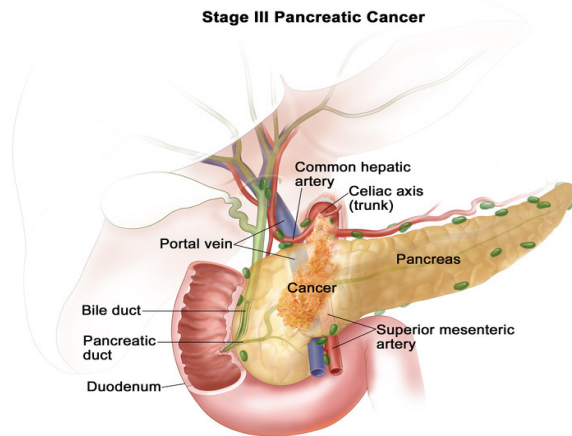


© 2012 Terese Winslow LLC
U.S. Govt. has certain rights

© DARTMOUTH-HITCHCOCK. ALL RIGHTS RESERVED.

Cancer Staging

Stage III Pancreatic Cancer

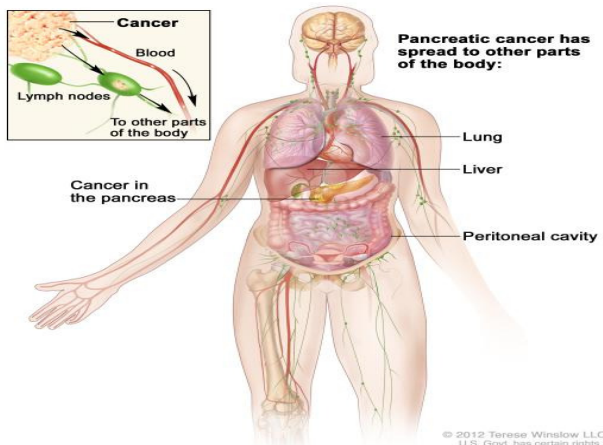


© 2012 Terese Winslow LLC
U.S. Govt. has certain rights

© DARTMOUTH-HITCHCOCK. ALL RIGHTS RESERVED.



Cancer Staging

Stage IV Pancreatic Cancer

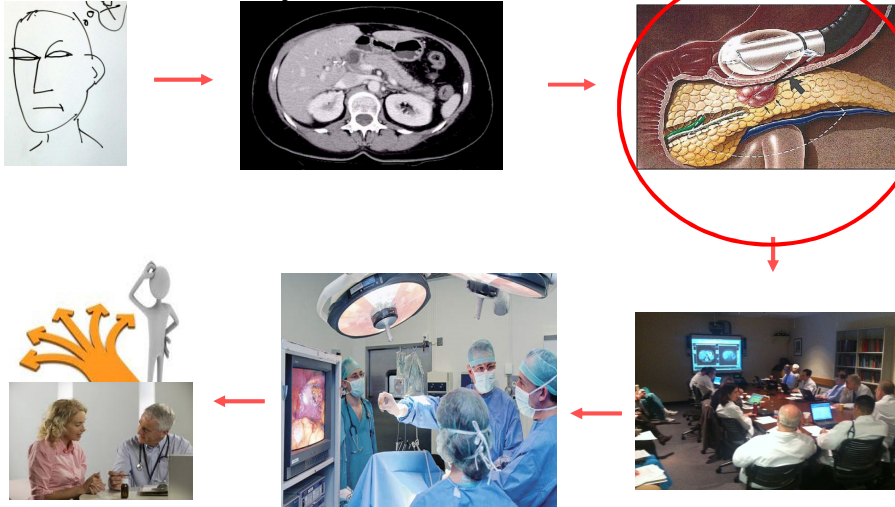


© 2012 Terese Winslow LLC
U.S. Govt. has certain rights



© DARTMOUTH-HITCHCOCK. ALL RIGHTS RESERVED.

Evaluation of Suspected Pancreatic Cancer

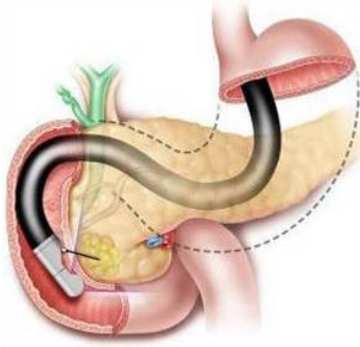


© DARTMOUTH-HITCHCOCK. ALL RIGHTS RESERVED.

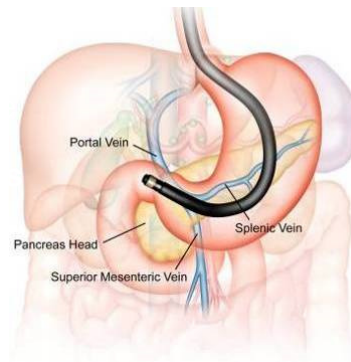
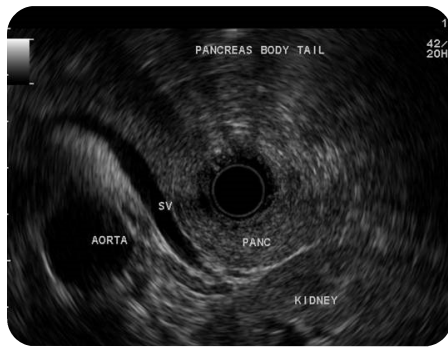
Endoscopic Ultrasound

- Imaging, diagnostic, and interventional capabilities
 - Identify organs, structures, vessels, lesions, cysts, fluid collections, etc.
- Less invasive
- Low risk
- High sensitivity

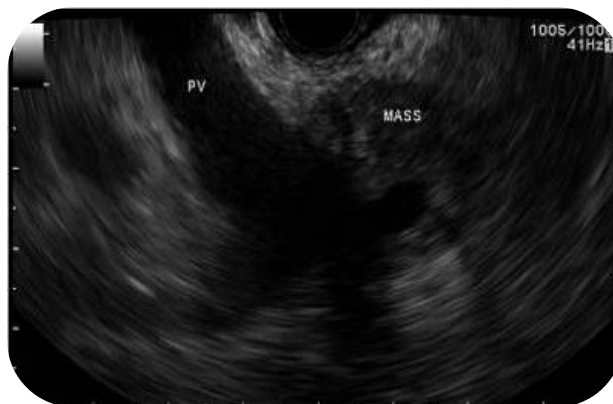

© DARTMOUTH-HITCHCOCK. ALL RIGHTS RESERVED.

Endoscopic Ultrasound




Endoscopic Ultrasound



Dartmouth-Hitchcock | GEISSEL SCHOOL OF MEDICINE AT DARTMOUTH

Endoscopic Ultrasound

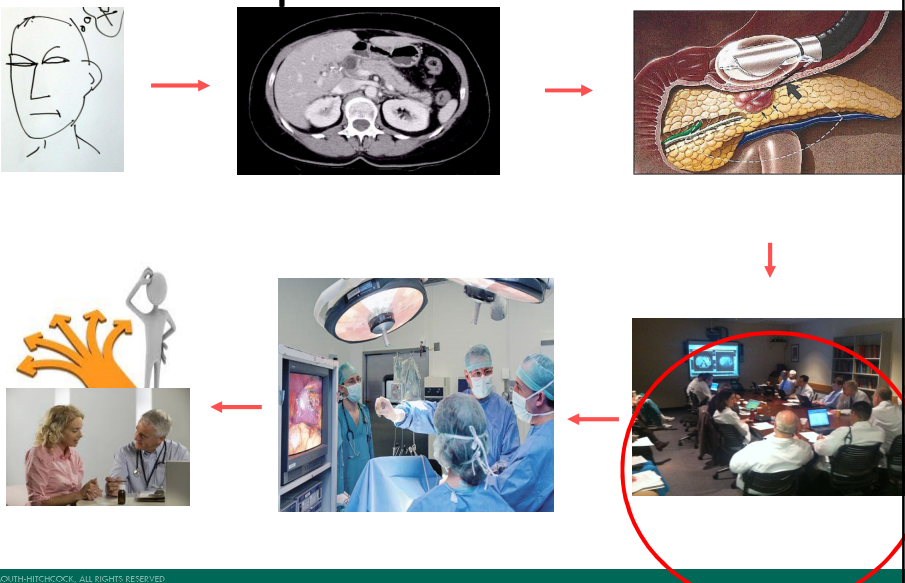


39

© DARTMOUTH-HITCHCOCK. ALL RIGHTS RESERVED.

Dartmouth-Hitchcock | GEISSEL SCHOOL OF MEDICINE AT DARTMOUTH

Evaluation of Suspected Pancreatic Cancer



```
graph LR; A[Patient] --> B[CT Scan]; B --> C[Anatomical Diagram]; C --> D[Operating Room]; D --> E[Meeting Room]; E --> F[Patient Consultation]
```

© DARTMOUTH-HITCHCOCK. ALL RIGHTS RESERVED.



Treatment

- Treatment and outcome depend upon stage at diagnosis
- Early stage pancreatic cancer can be CURED
- Advanced disease cannot...yet...
- Only research can cure cancer
- IDEAS...FUNDING...TRIAL PARTICIPATION

© DARTMOUTH-HITCHCOCK. ALL RIGHTS RESERVED.



Pancreatic Cancer Treatment

Surgical Resection

Radiotherapy

Chemotherapy

Combination Therapy

© DARTMOUTH-HITCHCOCK. ALL RIGHTS RESERVED.

Dartmouth-Hitchcock | **GRISB. GEORGE W. BROWN SCHOOL OF MEDICINE AT DARTMOUTH**

Resection Procedures

↙

“Whipple”

- Focal CP localized in the head
- Duodenal obstruction
- Biliary obstruction
- “Groove Pancreatitis”

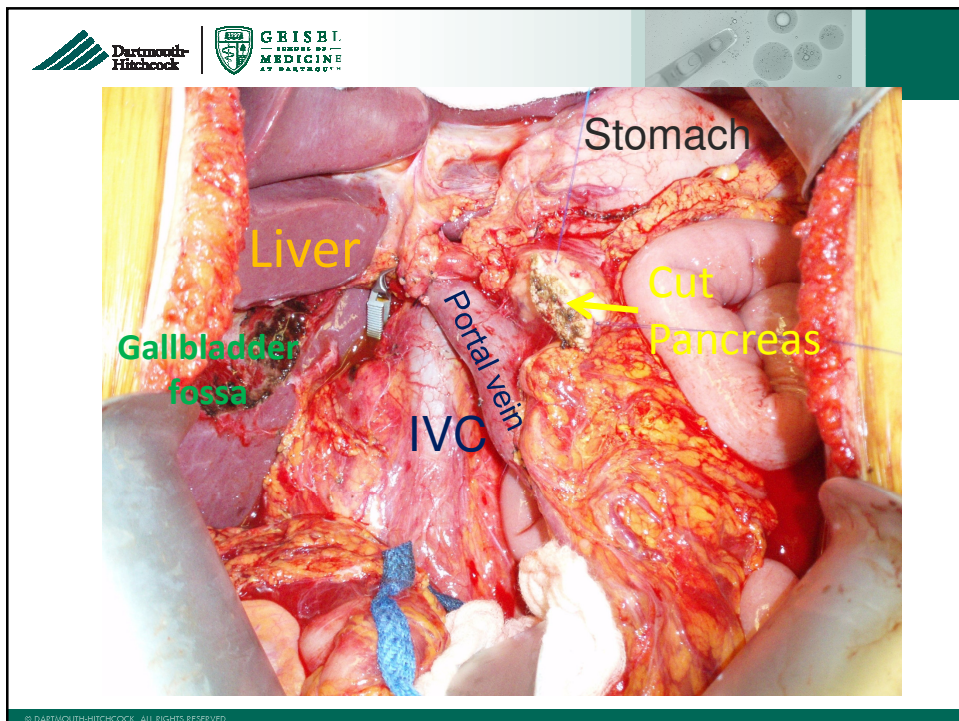
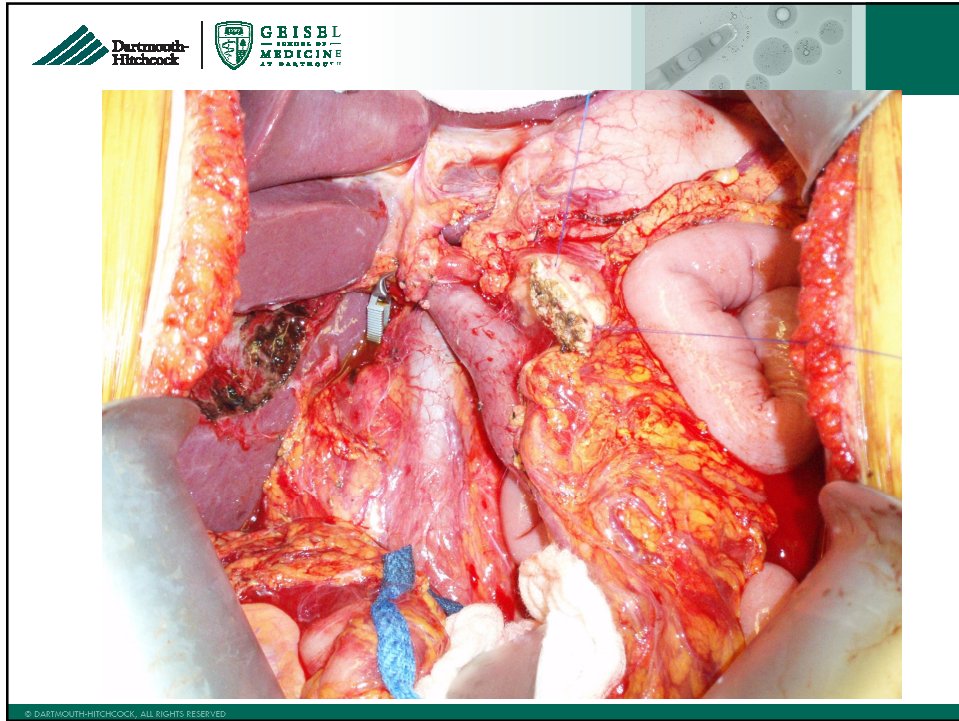
© DARTMOUTH-HITCHCOCK. ALL RIGHTS RESERVED.

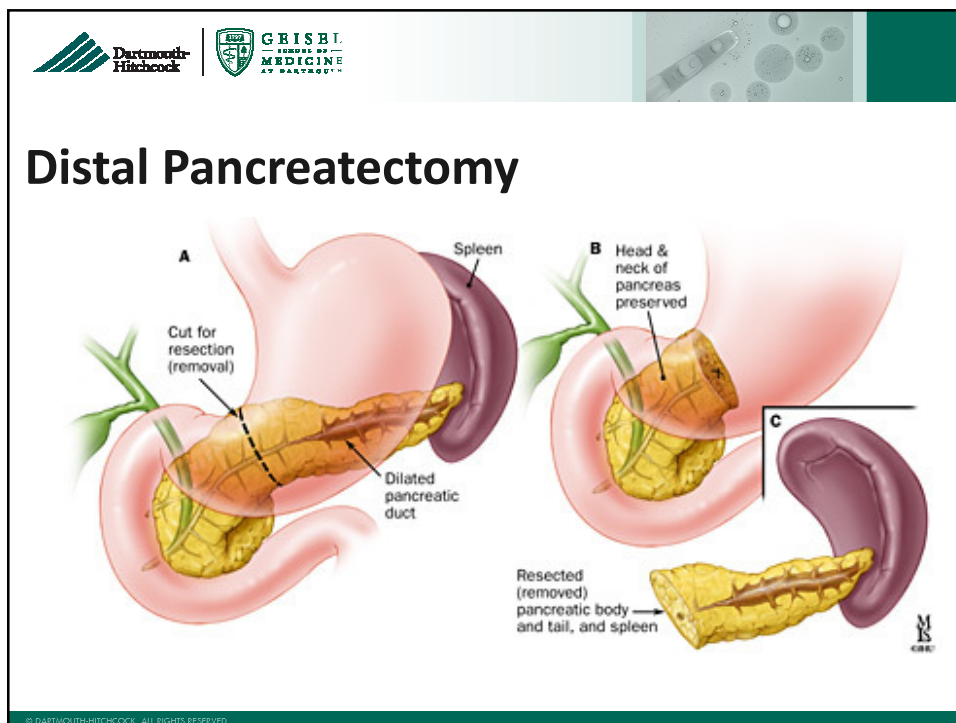
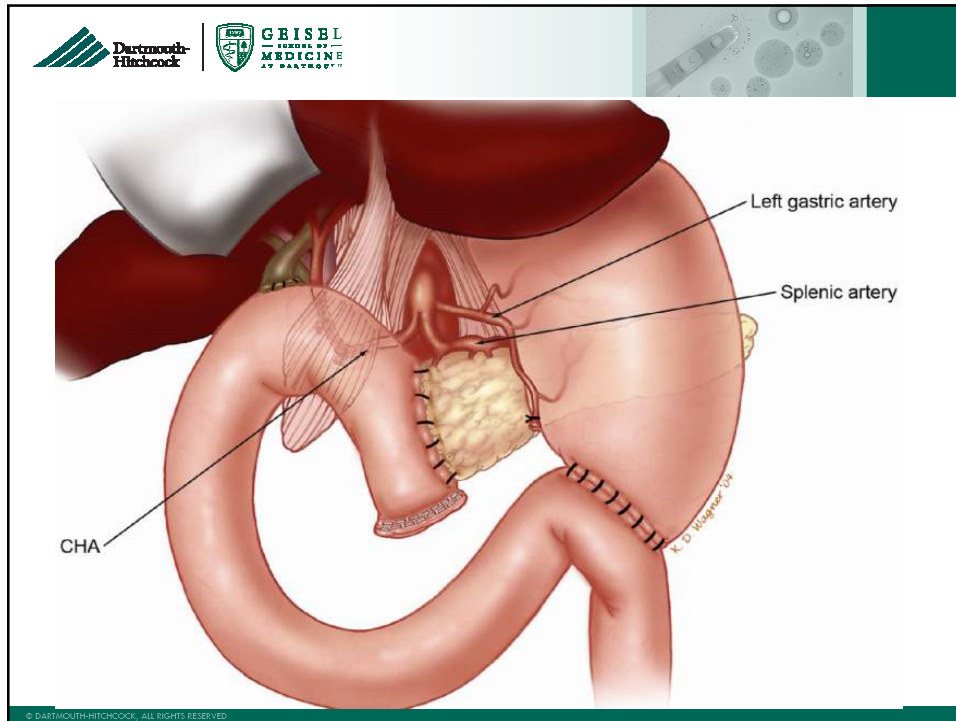
Dartmouth-Hitchcock | **GRISB. GEORGE W. BROWN SCHOOL OF MEDICINE AT DARTMOUTH**

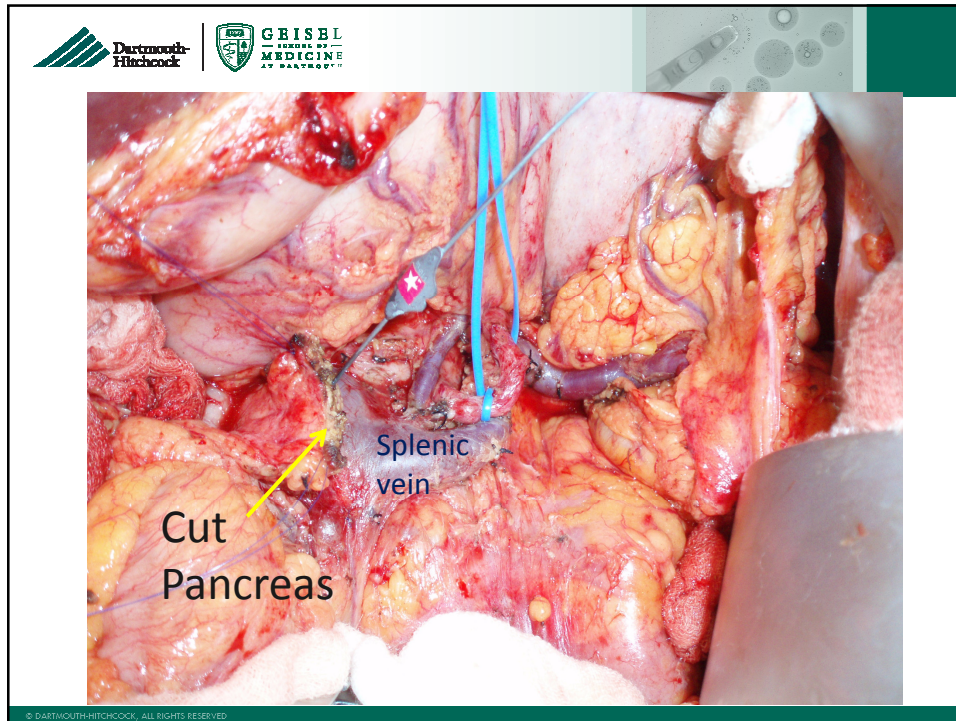
The “Whipple” procedure

Visual Aid © 2004
The University of Texas
M. D. Anderson Cancer Center

© DARTMOUTH-HITCHCOCK. ALL RIGHTS RESERVED.







Dartmouth-Hitchcock | GEISSEL SCHOOL OF MEDICINE AT DARTMOUTH

Is there a screening test?

PSA Test
Prostate Cancer Screening

Home Collection Kit
CLIA Certified Laboratory

WHY I WON'T
get a
MAMMOGRAM

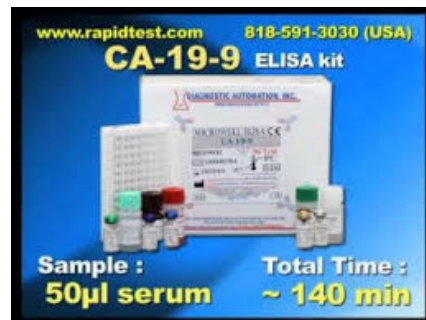Good for you!
This certifies that _____
was a Grownup
and got a Colonoscopy

© DARTMOUTH-HITCHCOCK. ALL RIGHTS RESERVED.

Is there a screening test?

CA 19-9

- Blood test
- Not elevated in all cancers
- Good way to track cancer after diagnosis



© DARTMOUTH-HITCHCOCK. ALL RIGHTS RESERVED.

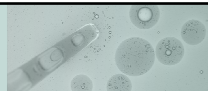
Is there a screening test?

Mesothelin

- Dipstick test
- Potential early screening test
- Not validated



© DARTMOUTH-HITCHCOCK. ALL RIGHTS RESERVED.



Is there a screening test?

In 2015, there is no accepted diagnostic screening test for pancreatic cancer that is inexpensive and able to detect early cancer

But we are certainly trying...

© DARTMOUTH-HITCHCOCK. ALL RIGHTS RESERVED.



Thank you



© DARTMOUTH-HITCHCOCK. ALL RIGHTS RESERVED.



Thank you for your participation.

If you have questions, please contact Patient Central at
(877) 272-6226 or e-mail patientcentral@pancan.org.

www.pancan.org or wagehope.org

